

**Dermabond®**

DERMABOND® Mini  
Topical Skin Adhesive  
**Evidence Brief**



## Overview

As the final layer of wound closure, topical skin adhesives (TSAs) are an integral part of a successful clinical outcome. When deciding which TSA to use, clinical study information on closure strength, microbial protection, patient comfort, and cosmesis allows healthcare practitioners to evaluate which product will provide the greatest benefits for their patients.

DERMABOND® Mini Topical Skin Adhesive is backed by an extensive body of published literature, including 51 Randomized Controlled Trials (RCTs). DERMABOND Mini has a patented, proprietary chemical formulation<sup>1</sup> that has been shown to provide superior strength versus other commercially available TSAs,<sup>2\*</sup> and also has benefits that enhance patient comfort and cosmetic outcomes.<sup>3,6</sup>

This Evidence Summary includes a sample of the available RCTs for DERMABOND® Topical Skin Adhesive.

**A full list of published studies can be found in the bibliography section of this document.**

- DERMABOND Mini is Supported by 51 Published RCTs<sup>†</sup>
- Total of 5,718 Patients Evaluated

\*Based on animal model

†DERMABOND Mini tests equivalent to DERMABOND Adhesive in head-to-head testing for microbial barrier, wound-bursting strength, tensile strength, flexibility, durability, viscosity, drying time, water vapor transmission rate, water resistance, and physician satisfaction

‡Based on published literature in PubMed and SCOPUS, using only RCTs that evaluated the use of the product in a manner consistent with intended indication

### References

1. Data on File. Ethicon, Inc. LAB0012182DNX12.
2. Singer AJ, Perry LC, Allen RL. In vivo study of wound-bursting strength and compliance of topical skin adhesives. *Acad Emerg Med*. 2008;15(12):1290-1294.
3. Nipshagen MD, Hage JJ, Beekman W. Use of 2-octyl-cyanoacrylate skin adhesive (Dermabond) for wound closure following reduction mammoplasty: a prospective, randomized intervention study. *Plast Reconstr Surg*. 2008;122:10-18.
4. Scott GR, Carson CL, Borah G. Dermabond skin closures for bilateral reduction mammoplasties: A review of 255 consecutive cases. *Plast Reconstr Surg*. 2007;120:1460-1465.
5. Toriumi DM, O'Grady K, Desai D, Bagal A. Use of octyl-2-cyanoacrylate for skin closure in facial plastic surgery. *Plast Reconstr Surg*. 1998;102:2209-2219.
6. Quinn J, Wells G, Sutcliffe T, et al. A randomized trial comparing octylcyanoacrylate tissue adhesive and sutures in the management of lacerations. *JAMA*. 1997;277(19):1527-1530.

## DERMABOND® Mini Topical Skin Adhesive

### A protective barrier that adds strength and inhibits bacteria

- Clinically shown to provide 7-day wound holding strength in just 3 minutes<sup>1</sup>
- Provides a microbial barrier with 99% protection in vitro for 72 hours against organisms commonly responsible for SSIs<sup>2\*</sup>
- Demonstrates inhibition of gram-positive bacteria (MRSA and MRSE) and gram-negative bacteria (*E. coli*) in vitro<sup>3†</sup>



\**S. epidermidis, E. coli, S. aureus, P. aeruginosa, E. faecium*

†Clinical significance unknown

#### References

1. Quinn J, Wells G, Sutcliffe T, et al. A randomized trial comparing octylcyanoacrylate tissue adhesive and sutures in the management of lacerations. *JAMA*. 1997;277:1527-1530.
2. Bhende S, Rothenburger S, Spangler DJ, Dito M. In vitro assessment of microbial barrier properties of DERMABOND® Topical Skin Adhesive. *Surg Infect*. 2002;3(3):251-257.
3. Data on File. Ethicon, Inc. In vitro evaluation of the viability of microorganisms after direct contact with DERMABOND® Topical Skin Adhesive. 2010.

## Summary of Key Studies

The publications that support the claims for DERMABOND® Mini Topical Skin Adhesive are listed in the table below.\* A summary of each of these studies can be found on the subsequent pages.

Publication Title	Lead Author	Source	Outcome Studied
In Vivo Study of Wound Bursting Strength and Compliance of Topical Skin Adhesives	Singer	<i>Academic Emergency Medicine.</i> 2008;15(12):1290-1294.	Strength and Flexibility
A Randomized Trial Comparing Octylcyanoacrylate Tissue Adhesive and Sutures in the Management of Lacerations	Quinn	<i>JAMA.</i> 1997;277(19):1527-1530.	Cosmesis, Time, Pain
Randomized Prospective Study Comparing Conventional Subcuticular Skin Closure With Dermabond Skin Glue After Saphenous Vein Harvesting	Krishnamoorthy	<i>Annals of Thoracic Surgery.</i> 2009;88(5):1445-1449.	Cosmesis, Time, Satisfaction
In vitro Assessment of Microbial Barrier Properties of DERMABOND® Topical Skin Adhesive	Bhende	<i>Surgical Infections.</i> 2002;3(3):251-257.	Microbial Barrier
Postoperative Outcomes Associated with Topical Skin Adhesives among Women Having Hysterectomies	Murmann	<i>Surgical Infections.</i> 2010;11(5):441-447.	Hospitalization Costs

\*DERMABOND Mini tests equivalent or superior to DERMABOND Adhesive in head-to-head testing for microbial barrier, wound-bursting strength, tensile strength, flexibility, durability, viscosity, drying time, water vapor transmission rate, water resistance, and physician satisfaction.

## Clinical Reference Article Summary

# In Vivo Study of Wound Bursting Strength and Compliance of Topical Skin Adhesives

Singer AJ, Perry LC, Allen RL Jr

### Source:

*Academic Emergency Medicine*. 2008;15(12):1290-1294

## Study Objective

The purpose of this study was to evaluate the wound bursting strength and flexibility of five topical skin adhesives during the two day period after wound closure.

### The following adhesives were evaluated in the study:

DERMABOND® Topical Skin Adhesive

INDERMIL® Tissue Adhesive

Histoacryl® Topical Skin Adhesive

LiquiBand® Topical Skin Adhesive

GluStitch®

## Method

Using a template for incision length and location, two symmetric incisions (2 cm long each) were created over the dorsolateral flank area of 210 anesthetized, male Sprague-Dawley rats.

After achieving hemostasis and manually approximating the skin edges, a randomized computer algorithm was used to select an adhesive to close the incision. All adhesives were applied according to manufacturers instructions.

The adhesives were evaluated three times during the study - immediately after closure, 1 day after closure, and 2 days after closure.

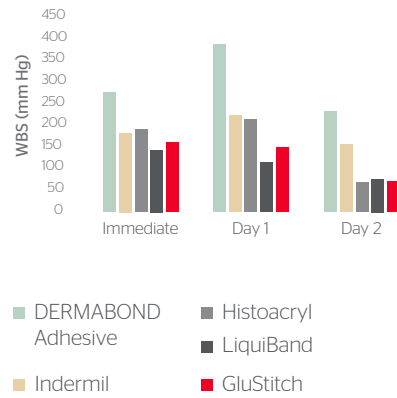
For each evaluation, 14 samples from each adhesive group were tested for wound bursting strength, and another 14 samples were tested for flexibility.

To test for wound bursting strength, a vacuum chamber was placed over each sample and negative pressure was applied, stressing the wound in 3 dimensions. The pressure (mmHg) needed to cause wound failure was recorded.

To test for flexibility, a vacuum chamber was placed over the sample and negative pressure was applied to the wound while a laser measured the vertical deformation of the skin ( $\mu\text{m}$ ). Energy absorption (mmHg x mm) was calculated to quantify the adhesives' flexibility.

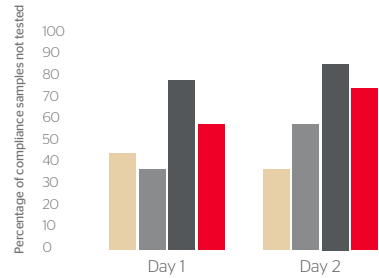
# Results

**Figure 1**  
Wound-bursting Strength



In total, 210 measurements were taken on 210 incisions (5 adhesives, 3 time points, 14 samples per time point). Results are shown in **Figure 1**.

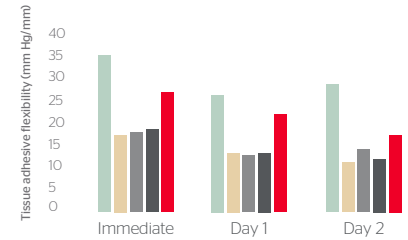
**Figure 2**  
Percent of Samples with Visible Fractures



With the exception of the samples in the DERMABOND® Topical Skin Adhesive group, measurements could not be taken on all samples in an adhesive group because, in some samples, the adhesive's inflexibility had caused the adhesive to fracture during testing.

As shown in **Figure 2**, the percent of samples in an adhesive group experiencing fractures ranged from 36% to 86%.

**Figure 3**  
Flexibility of Five Topical Skin Adhesives



As seen in **Figure 3**, for the samples that maintained their integrity through the testing, the samples in the DERMABOND Adhesive group consistently had the greatest flexibility. Additionally, across all adhesive groups, the adhesive's flexibility decreased over time.

## Conclusion

The results of this study demonstrate that DERMABOND Adhesive was significantly stronger and more flexible than the other adhesives evaluated in the study.\*

\*This study was funded in full or in part by an educational grant from Ethicon, Inc.

The third-party trademarks used herein are trademarks of their respective owners.

## Clinical Reference Article Summary

# A Randomized Trial Comparing Octylcyanoacrylate Tissue Adhesive and Sutures In the Management of Lacerations

Quinn J, Wells G, Sutcliffe T, et al.

### Source:

JAMA. 1997;277(19):1527-1530

## Study Objective

The purpose of this study was to assess whether using DERMABOND® Topical Skin Adhesive for laceration repair is an effective alternative to suturing.

## Method

Patients with non-mucosal facial lacerations as well as certain extremity and torso lacerations, but not on hands, feet or joints, were eligible for this study.

Using a computer algorithm, patients were prospectively segregated into facial and non-facial groups and randomized into two groups - DERMABOND Adhesive and sutures.

In the suture group, lacerations were anesthetized and cleaned, as needed, before repair with a 5-0 or 6-0 monofilament suture. A dressing was applied for at least 48 hours.

In the DERMABOND Adhesive group, lacerations were cleaned with chlorhexidene, and hemostasis was achieved using pressure or topical 1:1000 epinephrine. The wound edges were manually approximated and the adhesive was applied to the surface of the skin, covering the wound edges. The wound was held in place for 30 seconds. No dressing was applied.

The primary outcome was the cosmetic appearance of the scar, evaluated by a blinded plastic surgeon using a photograph of the wound taken three months after closure.

On two occasions, the surgeon examined the photograph and provided a cosmesis score based on a validated 100-mm visual analog scale, ranging from "best scar" to "worst scar."

Additionally, time of procedure, patient pain, and wound complications (i.e., dehiscence, infection) were recorded. Time of procedure was evaluated from start of wound care to complete closure; patient pain and wound complications were recorded on a previously validated scale.

Wound complication was initially evaluated at 3-5 days for facial and at 10-14 days for torso and extremity lacerations. A second assessment occurred 3 months after closure.

## Results

In total, 130 patients with 136 lacerations were included in the study. As summarized in **Figure 1**, an equal number of lacerations (68 per group) were randomized to the suture and DERMABOND Adhesive groups.

**Figure 1**  
Patient Retention During Study

	DERMABOND Adhesive	Suture
Randomized	68	68
Initial follow-up	53	53
3 month follow-up	55	50
Withdrawn	1	1
Lost to follow-up	12	17
No Photographs	5	2
<b>Completed Study</b>	<b>50</b>	<b>48</b>

As shown in **Figure 2**, there was no significant difference in the blinded, 3-month cosmetic score of the DERMABOND® Topical Skin Adhesive group compared with the suture group. Similarly, there was no significant difference in wound complications between the suture group and the DERMABOND Adhesive group. Statistically significant differences were seen for patient pain and procedure time.

**Figure 2**  
Summary of Observed Clinical Outcomes

	<b>DERMABOND Adhesive</b>	<b>Suture</b>	<b>(p) Value</b>
Mean Cosmetic Score	67	68	0.65
% Optimal Wound Scores (initial eval)	80%	82%	0.80
% Optimal Wound Scores (3 month eval)	72%	75%	0.74
<b>Mean Pain Scores</b>	<b>7.2</b>	<b>18.0</b>	<b>&lt;0.001</b>
<b>Mean Time of Procedure (min)</b>	<b>3.6</b>	<b>12.4</b>	<b>&lt;0.001</b>

## Conclusions

The results of this study demonstrate that DERMABOND Adhesive produces cosmetic results similar to suturing on certain types of lacerations.

Additionally, lacerations closed with DERMABOND Adhesive were associated with shorter procedure time and less patient pain than lacerations closed with sutures.\*

## Clinical Reference Article Summary

# Randomized Prospective Study Comparing Conventional Subcuticular Skin Closure with Dermabond Skin Glue After Saphenous Vein Harvesting

Krishnamoorthy BS, Najam O, Khan UA, et al.

### Source:

*The Annals of Thoracic Surgery*. 2009;88(9):1445-1449

## Study Objective

The purpose of this study was to compare cosmetic appearance, procedure time, and patient satisfaction associated with wounds closed by DERMABOND® Topical Skin Adhesive versus traditional subcuticular skin sutures after coronary artery bypass graft (CABG) surgery.

## Method

Patients undergoing elective CABG surgery were eligible for this prospective, randomized, controlled, single-center study.

For the closure of the incision created to harvest the saphenous vein, patients were randomized, using a computer algorithm, into two groups - wound closure using sutures and wound closure using DERMABOND Adhesive.

To harvest the vein, a minimally invasive vein harvesting (bridging) technique was used. During the procedure, incisions approximately 2-3 cm in size were made over the length of the vein, leaving 6-7 cm gaps between incisions.

In the suture group, continuous subcuticular and subcutaneous technique was performed using an absorbable, monofilament synthetic suture. After closure, the wound was covered with a bandage and a pressure dressing was applied for 48 hours.

In the DERMABOND Adhesive group, the wound was first closed with subcutaneous sutures. Then, the wound edges were approximated and the adhesive was applied to the surface of the skin. Two layers of adhesive were applied to the skin, taking care to cover the edges of the wound. Steri-Strips™ and a pressure bandage were used to hold the edges together for 24 hours.

### Cosmetic Appearance

Photographs of the wound were taken seven days post-discharge and again at six weeks post discharge. Two surgeons, blinded to the study, evaluated the photographs. For the Day 7 assessment, the surgeons used the previously validated Hollander wound evaluation grading scale. For the Week 6 assessment, the surgeons used the Vancouver Scar Scale.

### Procedure Time

The amount of time that elapsed between the end of vein harvesting and the completion of wound closure was recorded by an OR technician not involved in the study.

### Patient Satisfaction

Patients were asked to evaluate their satisfaction with the cosmetic outcome of their scar at time of discharge and at six weeks postoperatively using a modified version of the Patient and Observer Scar Assessment and the visual analog scale.

## Results

In total, 106 patients were randomized and treated in this study – 53 in the suture group, and 53 in the DERMABOND® Topical Skin Adhesive group. There were an additional 12 patients that were excluded from this study due to a high risk of vein harvesting failure during the procedure.

### Cosmetic Appearance

For the scars evaluated at Day 7 using the Hollander wound evaluation grading scale, scores had the potential to range from 0 to 6 where a score of 0 reflects optimal cosmesis. All scars (n=53) in the DERMABOND Adhesive group were assessed a score of 0.

Appearance of scars in the suture group (n=53) ranged from 1 to 4; no scars in the suture group achieved a score of 0. The difference in cosmesis was statistically significant ( $p < 0.001$ ). Results are shown in **Figure 1**.

For the six-week evaluation using the Vancouver Scar Scale, the appearance of scars in the DERMABOND Adhesive group was significantly better than the appearance of scars in the suture group ( $p = 0.001$ ).

At six weeks, there was not a significant difference in incidence of inflammation, hematoma, or exudation between the groups.

### Procedure Time

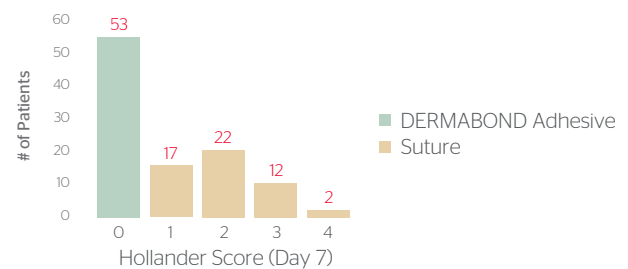
As seen in **Figure 2**, there was not a statistically significant difference in total operating time between the two groups, but the median amount of time necessary to close the skin was significantly less in the DERMABOND Adhesive group compared with the suture group.

### Patient Satisfaction

There was no significant difference in patient satisfaction scores at time of discharge. However, at the six-week evaluation, patient satisfaction was significantly better in the DERMABOND Adhesive group than the suture group ( $p < 0.001$ ).

Specifically, patients were more satisfied with the color and visibility of the scar at six weeks when DERMABOND Adhesive was used.

**Figure 1**  
Day 7 Cosmetic Appearance Scores



**Note:** A score of 0 reflects optimal cosmetic appearance

**Figure 2**  
Median Procedure Time

Variable	DERMABOND Adhesive	Suture	(p) value
Total Operation Time (min)	45	45	0.43
Skin Closure Time (min)	10.75	13.17	0.017

## Conclusion

The results of this study demonstrate that using DERMABOND Adhesive instead of traditional subcuticular suture to close incisions during CABG procedures may lead to superior cosmetic appearance, shorter skin closure time, and greater patient satisfaction.\*

## Clinical Reference Article Summary

# In Vitro Assessment of Microbial Barrier Properties of DERMABOND® Topical Skin Adhesive

Bhende S, Rothenburger S, Spangler D, Dito M

### Source:

*Surgical Infections*. 2002;3(3):251-257

## Study Objective

The purpose of this study was to evaluate the ability of DERMABOND Adhesive to provide an effective microbial barrier against the penetration of microorganisms in vitro.

### Bacteria used in this study included:

*Staphylococcus aureus*

*Staphylococcus epidermidis*

*Escherichia coli*

*Pseudomonas aeruginosa*

*Enterococcus faecium*

## Method

Plates containing an agar media were created in a sterile environment. The agar media contained a pH-sensitive dye designed to color when exposed to the acidic metabolic products of bacteria.

DERMABOND Adhesive was applied to the agar surface. In total, 300 single-layer films and 300 triple-layer films were examined. The surface of each film was inoculated with a 10  $\mu$ L aliquot of bacteria containing at least  $1 \times 10^3$  cfu.

All test and control plates were incubated at 37°C for 72 hours. A change in color indicated a breach in the adhesive's microbial barrier.

## Results

Single-layer films: 299 of the 300 samples retained their integrity as microbial barriers for 72 hours.

All 300 samples maintained their microbial barrier for 48 hours.

For the triple-layer films, 299 of the 300 samples retained their integrity as microbial barriers for 72 hours.

## Conclusion

The results of this study demonstrate that DERMABOND Adhesive provides a microbial barrier with 99% protection in vitro for at least 72 hours against organisms commonly responsible for SSIs, including: *Staphylococcus epidermidis*, *Staphylococcus aureus*, *Escherichia coli*, *Pseudomonas aeruginosa*, and *Enterococcus faecium*.

## Clinical Reference Article Summary

# Postoperative Outcomes Associated with Topical Skin Adhesives among Women Having Hysterectomies

Murmann SG, Markowitz JS, Gutterman EM, Magee G

### Source:

*Surgical Infections*. 2010;11(5):441-447

## Study Objective

The purpose of this study was to evaluate the clinical and economic outcomes associated with use of a topical skin adhesive (TSA) versus traditional methods for skin closure following total abdominal hysterectomy.

## Method

The study utilized Premier, Inc.'s Perspective™ Comparative Database, which is a large, administrative database containing clinical and economic data from all patient discharge records at more than 400 US hospitals.

Any patient in the database who was discharged from a hospital in 2005 following a total abdominal hysterectomy was included in the study.

**The subjects were classified into one of four treatment groups based on the clinical method used to close the surgical incision:**

- Sutures
- Staples
- TSA
- Staples and TSA

While the study was open to all commercially available TSAs, at the time of the study, the only TSA used on patients was DERMABOND® Topical Skin Adhesive. Thus, the TSA group only had patients treated with DERMABOND Adhesive.

All treatment groups were assessed on three continuous outcomes: length of inpatient stay, total inpatient cost, and days of antibiotic treatment. Length of stay and inpatient cost was available directly from the database; antibiotic treatment days were estimated using the last date when at dose of antibiotic was administered.

## Results

In total, 46,011 patients were included in the study. The method of wound closure for these patients is summarized in **Figure 1**.

Due to the large sample size, there were no statistically significant differences in the clinical, demographic, or hospital characteristics of the four treatment groups.

**Figure 1**  
Distribution of Skin Closure Method

Skin Closure Method Evaluated in Study	# of Patients (n)
Sutures	21,201
Staples	23,441
TSA	880
Staples and TSA	489
<b>All Methods</b>	<b>46,011</b>

### Length of Stay (LOS) and Total Costs

A summary of mean LOS and total hospitalization costs is shown in **Figure 2**.

While the difference in total costs between suture and TSA groups did not meet the significance requirement for this study ( $p \leq 0.01$ ), the difference suggests lower total costs for the TSA group ( $p = 0.039$ ).

**Figure 2**

LOS and Total Costs by Closure Method

Skin Closure Method Evaluated in Study	Mean LOS (days)	Mean Total Hospitalization Costs
Sutures	3.9	\$5,862
Staples	4.5	\$6,965
TSA	3.7	\$5,816
Staples and TSA	5.2	\$9,434

## Conclusions

The results of this study demonstrate that the clinical and economic outcomes were consistently worse when staples were used to close an incision compared with use of suture or TSA alone.

The clinical outcomes resulting from the use of DERMABOND Adhesive to close wounds were at least as good as the outcomes resulting from the use of suture to close wounds.

Additionally, there is evidence that the total costs of hospitalization for total hysterectomy patients may be less when the incision is closed with DERMABOND Adhesive versus sutures or staples.\*

\*This study was funded in full or in part by an educational grant from Ethicon, Inc. For complete indications, contraindications, warnings, precautions, and adverse reactions, please reference full package insert.

# For More Information

**Call 1-877-ETHICON (384-4266)**

In addition to support from Ethicon Sales Representatives, Ethicon's Medical Affairs team is available to provide balanced, non-promotional scientific information to healthcare professionals.

## Medical information request form

**To: Ethicon Medical Affairs**

E-mail: [Eth\\_Medical\\_Info@its.jnj.com](mailto:Eth_Medical_Info@its.jnj.com) Voicemail: (800) 888-9234, x3800

Date: \_\_\_\_\_

From (Requestor): \_\_\_\_\_

Name: \_\_\_\_\_

(Circle one):

M.D.

D.O.

R.N.

N.P.

Pharm.D.

Ph.D.

R.Ph.

Other: \_\_\_\_\_

Title: \_\_\_\_\_ Institution/Office: \_\_\_\_\_

Address: \_\_\_\_\_

City: \_\_\_\_\_ State: \_\_\_\_\_ ZIP: \_\_\_\_\_

Telephone: \_\_\_\_\_ Fax: \_\_\_\_\_

E-mail Address: \_\_\_\_\_

Desired Response Method (Circle one):

US Mail

Phone

E-mail

Fax

Meeting with Medical Affairs Representative

Requestor's Signature:

(REQUIRED FOR PROCESSING) \_\_\_\_\_

Please send medical information on the following topic(s):

(Be as specific as possible with respect to product topic, area of use, outcome of interest, etc.)

\_\_\_\_\_  
\_\_\_\_\_  
\_\_\_\_\_

Sales Representative: \_\_\_\_\_ Territory: \_\_\_\_\_

PRINT FULL NAME \_\_\_\_\_

## Bibliography

Listed below are all of the currently published RCTs that have evaluated the use of DERMABOND® Topical Skin Adhesive in an application consistent with the indication in the product's label (e.g. skin closure). Studies that evaluated the use of DERMABOND Adhesive for purposes inconsistent with the intended indication were excluded from the bibliography.

- Amin M, Glynn F, Timon C. Randomized trial of tissue adhesive vs staples in thyroidectomy integrating patient satisfaction and Manchester score. *Otolaryngol Head Neck Surg.* 2009;140(5):703-8.
- Blondeel, PNV, Murphy JW, Debrosse D, Nix III JC, Puls LE, Theodore N, Coulthard P. Closure of long surgical incisions with a new formulation of 2-octylcyanoacrylate tissue adhesive versus commercially available methods. *Am J Surg.* 2004;188(3):307-313.
- Brown JK, Campbell BT, Drongowski RA, Alderman AK, Geiger JD, Teitelbaum DH, Quinn J, Coran AG, Hirschl RB. A prospective, randomized comparison of skin adhesive and subcuticular suture for closure of pediatric hernia incisions: cost and cosmetic considerations. *J Pediatr Surg.* 2009;44(7):1418-1422.
- Bruns TB, Robinson BS, Smith RJ, Kile DL, Davis TP, Sullivan KM, Quinn JV. A new tissue adhesive for laceration repair in children. *J Pediatr.* 1998;132(6):1067-1070.
- Carleo C, Singer AJ, Thode HC Jr. Effect of frequent water immersion on the rate of tissue adhesive sloughing: a randomized study. *CJEM.* 2005;7(6):391-395.
- Chen K, Klapper AS, Voige H, Del Priore G. A randomized, controlled study comparing two standardized closure methods of laparoscopic port sites. *JSLS.* 2010;14(3):391-394.
- El-Gazzar Y, Smith DC., Kim S.J., Hirsh DM., Blum Y., Cobelli M., Cohen H.W. The Use of Dermabond® as an Adjunct to Wound Closure After Total Knee Arthroplasty: Examining Immediate Post-Operative Wound Drainage. *J Arthroplasty.* 2013;28:553-556.
- Eymann R, Kiefer M. Glue instead of stitches: a minor change of the operative technique with a serious impact on the shunt infection rate. *Acta Neurochir Suppl.* 2010;106:87-89.
- Gennari R, Rotmensz N, Ballardini B, Scevola S, Perego E, Zanini V, Costa A. A prospective, randomized, controlled clinical trial of tissue adhesive (2-octylcyanoacrylate) versus standard wound closure in breast surgery. *Surgery.* 2004;136(3):593-599.
- Greene D, Koch RJ, Goode RL. Efficacy of octyl-2-cyanoacrylate tissue glue in blepharoplasty. A prospective controlled study of wound-healing characteristics. *Arch Facial Plast Surg.* 1999;1(4):292-296.
- Handschel JG, Depprich RA, Dirksen D, Runte C, Zimmermann A, Kübler NR. A prospective comparison of octyl-2- cyanoacrylate and suture in standardized facial wounds. *Int J Oral Maxillofac Surg.* 2006;35(4):318-323.
- Holger JS, Wandersee SC, Hale DB. Cosmetic outcomes of facial lacerations repaired with tissue-adhesive, absorbable, and nonabsorbable sutures. *Am J Emerg Med.* 2004;22(4):254-257.
- Hollander JE, Singer AJ. Application of tissue adhesives: rapid attainment of proficiency. *Acad Emerg Med.* 1998;5(10):1012-1017
- Jallali N, Haji A, Watson CJ. A prospective randomized trial comparing 2-octyl cyanoacrylate to conventional suturing in closure of laparoscopic cholecystectomy incisions. *J Laparoendosc Adv Surg Tech A.* 2004;14(4):209-211.
- Kent A., Liversedge N., Dobbins B., McWhinnie D., Jan H. A prospective, randomized, controlled, double-masked, multi-center clinical trial of medical adhesives for the closure of laparoscopic incisions. *J Minim Invasive Gynecol.* 2014;21:252-258.
- Khan RJ, Fick D, Yao F, Tang K, Hurworth M, Nivbrant B, Wood D. A comparison of three methods of wound closure following arthroplasty: a prospective, randomised, controlled trial. *J Bone Joint Surg Br.* 2006;88(2):238-242.
- Koonce SL, Eck DL, Shaddix KK, Perdakis G. A prospective randomized controlled trial comparing N-butyl-2 cyanoacrylate (Histoacryl), octyl cyanoacrylate (Dermabond), and subcuticular suture for closure of surgical incisions. *Ann Plast Surg.* 2015;74:107-110.
- Krishnamoorthy B, Najam O, Khan UA, Waterworth P, Fildes JE, Yonan N. Randomized prospective study comparing conventional subcuticular skin closure with Dermabond skin glue after saphenous vein harvesting. *Ann Thorac Surg.* 2009;88(5):1445-1449.
- Maartense S, Bemelman WA, Dunker MS, de Lint C, Pierik EG, Busch OR, Gouma DJ. Randomized study of the effectiveness of closing laparoscopic trocar wounds with octylcyanoacrylate, adhesive papertape or polyglecaprone. *Br J Surg.* 2002;89(11):1370-1375.
- Maloney J, Rogers GS, Kapadia M. A prospective randomized evaluation of cyanoacrylate glue devices in the closure of surgical wounds. *J Drugs Dermatol.* 2013;12:810-814.
- Man SY, Wong EM, Ng YC, Lau PF, Chan MS, Lopez V, Mak PS, Graham CA, Rainer TH. Cost-consequence analysis comparing 2-octyl cyanoacrylate tissue adhesive and suture for closure of simple lacerations: A randomized controlled trial. *Ann Emerg Med.* 2009;53(2):189-197.
- Martin JG, Hollenbeck ST, Janas G, Makar RA, Pabon-Ramos WM, Suhocki PV, Miller MJ, Sopko DR, Smith TP, Kim CY. Randomized controlled trial of octyl cyanoacrylate skin adhesive versus subcuticular suture for skin closure after implantable venous port placement. *J Vasc Interv Radiol.* 2017;28:111-116.
- Mota R, Costa F, Amaral A, Oliveira F, Santos CC, Ayres-De-Campos D. Skin adhesive versus subcuticular suture for perineal skin repair after episiotomy - A randomized controlled trial. *Acta Obstet Gynecol Scand.* 2009;88(6):660-666.
- Mudd CD, Boudreau JA, Moed BR. A prospective randomized comparison of two skin closure techniques in acetabular fracture surgery. *J Orthop Traumatol.* 2014;15:189-194.

Nipshagen MD, Hage JJ, Beekman WH. Use of 2-octyl-cyanoacrylate skin adhesive (Dermabond) for wound closure following reduction mammoplasty: A prospective, randomized intervention study. *Plast Reconstr Surg*. 2008;122(1):10-18.

Ong CC, Jacobsen AS, Joseph VT. Comparing wound closure using tissue glue versus subcuticular suture for pediatric surgical incisions: A prospective, randomised trial. *Pediatr Surg Int*. 2002;18(5-6):553-555.

Ong J, Ho KS, Chew MH, Eu KW. Prospective randomised study to evaluate the use of DERMABOND ProPen (2- octylcyanoacrylate) in the closure of abdominal wounds versus closure with skin staples in patients undergoing elective colectomy. *Int J Colorectal Dis*. 2010;25(7):899-905.

Osmond MH, Quinn JV, Sutcliffe T, Jarmuske M, Klassen TP. A randomized, clinical trial comparing butylcyanoacrylate with octylcyanoacrylate in the management of selected pediatric facial lacerations. *Acad Emerg Med*. 1999;6(3):171-177.

Patel HM, Shah MJ, Duttaroy DD, Kacheriwala SM, Patel SJ, Patel RM. Superiority of octyl-2 cyanoacrylate over polyamide black for surgical site incisions. Prospective randomized trial. *Surg Chron*. 2013; 18(3):139-143.

Pronio A, Di Filippo A, Nariilli P, Caporilli D, Vestri A, Ciamberlano B, Pelle F, Montesani C. Closure of cutaneous incision after thyroid surgery: A comparison Quinn J, Wells G, Sutcliffe T, Jarmuske M, Maw J, Stiell I, Johns P. A randomized trial comparing octylcyanoacrylate tissue adhesive and sutures in the management of lacerations. *JAMA*. 1997;277(19):1527-1530.

Ridgway DM, Mahmood F, Moore L, Bramley D, Moore PJ. A blinded, randomised, controlled trial of stapled versus tissue glue closure of neck surgery incisions. *Ann R Coll Surg Engl*. 2007;89(3):242-246.

Romero P, Frongia G, Wingerter S, Holland-Cunz S. Prospective, randomized, controlled trial comparing a tissue adhesive (Dermabond) with adhesive strips (Steri-Strips) for the closure of laparoscopic trocar wounds in children. *Eur J Pediatr Surg*. 2011;21(3):159-162.

Sebesta MJ, Bishoff JT. Octylcyanoacrylate skin closure in laparoscopy. *JSL*. 2004;8(1):9-14.

Shamiyeh A, Schrenk P, Stelzer T, Wayand WJ. Prospective randomized blind controlled trial comparing sutures, tape, and octylcyanoacrylate tissue adhesive for skin closure after phlebectomy. *Dermatol Surg*. 2001;27(10):877-880.

Siddiqui M, Bidaye A, Baird E, Abu-Rajab R, Stark A, Jones B, Ingram R, Anthony I. Wound dressing following primary total hip arthroplasty: A prospective randomised controlled trial. *J Wound Care*. 2016;25-40.

Singer AJ, Giordano P, Fitch JL, Gulla J, Ryker D, Chale S. Evaluation of a new high-viscosity octylcyanoacrylate tissue adhesive for laceration repair: a randomized, clinical trial. *Acad Emerg Med*. 2003;10(10):1134-1137.

Singer AJ, Hollander JE, Valentine SM, Turque TW, McCuskey CF, Quinn JV. Prospective, randomized, controlled trial of tissue adhesive (2- octylcyanoacrylate) vs standard wound closure techniques for laceration repair. *Acad Emerg Med*. 1998;5(2):94-99.

Snizek PJ, Walling HW, DeBloom JR 3rd, Messingham MJ, VanBeek MJ, Kreiter CD, Whitaker DC, Arpey CJ. A randomized controlled trial of high-viscosity 2-octyl cyanoacrylate tissue adhesive versus sutures in repairing facial wounds following Mohs micrographic surgery. *Dermatol Surg*. 2007;33(8):966-971.

Soni A, Narula R, Kumar A, Parmar M, Sahore M, Chandel M. Comparing cyanoacrylate tissue adhesive and conventional subcuticular skin sutures for maxillofacial incisions - A prospective randomized trial considering closure time, wound morbidity, and cosmetic outcome. *J Oral Maxillofac Surg*. 2013 Dec;71(12):2152.e1-8.

Spencer S, Coban N, Koch L, Schirdewan A, Mueller D. Comparison of skin adhesive and absorbable intracutaneous suture for the implantation of cardiac rhythm devices. *Europace*. 2011;13:416-420.

Strauss EJ, Weil WM, Jordan C, Paksima N. A prospective, randomized, controlled trial of 2-octylcyanoacrylate versus suture repair for nail bed injuries. *J Hand Surg Am*. 2008;33(2):250-253.

Sun J, Chen Q-M, Zhang M, Shi C-R. Octylcyanoacrylate versus absorbable suture in the repair of skin wound in children. *Chinese J Clin Rehabilitation*. 2005;19:26-29.

Switzer EF, Dinsmore RC, North JH Jr. Subcuticular closure versus dermabond: A prospective randomized trial. *Am Surg*. 2003;69(5):434-436.

Tierney EP, Moy RL, Kouba DJ. Rapid absorbing gut suture versus 2 octylethylcyanoacrylate tissue adhesive in the epidermal closure of linear repairs. *J Drugs Dermatol*. 2009;8(2):115-119.

Toriumi DM, O'Grady K, Desai D, Bagal A. Use of octyl-2-cyanoacrylate for skin closure in facial plastic surgery. *Plast Reconstr Surg*. 1998;102(6):2209-2219.

Wong EM, Rainer TH, Ng YC, Chan MS, Lopez V. Cost-effectiveness of Dermabond versus sutures for lacerated wound closure: A randomised controlled trial. *Hong Kong Med J*. 2011;17:4-8.